



ISSN (E): 2320-3862
ISSN (P): 2394-0530
www.plantsjournal.com
JMPS 2019; 7(6): 179-184
© 2019 JMPS
Received: 26-09-2019
Accepted: 30-10-2019

Vikram Singh
Department of Chemistry,
NREC College, Khurja,
Bulandshahr, Uttar Pradesh,
India

Dharmendra Singh
(1) Centre for Advanced Studies,
Department of Zoology,
University of Rajasthan, Jaipur,
Rajasthan, India
(2) Department of Zoology, Dyal
Singh College, University of
Delhi, Lodhi Road, New Delhi,
Delhi, India

Corresponding Author:
Dharmendra Singh
(1) Centre for Advanced Studies,
Department of Zoology,
University of Rajasthan, Jaipur,
Rajasthan, India
(2) Department of Zoology, Dyal
Singh College, University of
Delhi, Lodhi Road, New Delhi,
Delhi, India

Suppression of fertility by *Capparis spinosa* root extract through antioxidant alteration in reproductive system of male rats

Vikram Singh and Dharmendra Singh

DOI: <https://doi.org/10.22271/plants.2019.v7.i6c.1413>

Abstract

Aim: To evaluate the suppression of fertility by oral mode of *Capparis spinosa* root extract through alteration in antioxidant defence of the reproductive system of male albino rats.

Methods: The methanol extract of *Capparis spinosa* root (100mg/kg/day) was fed for 60 days to male, Wistar strain, albino rats. The fertility and testicular functions were assessed by mating tests, antioxidant defence indices, and spermatogenesis, histometry, and biochemical estimations for fertility suppression along with serum biochemistry and hematology for assessment of toxicology.

Results: *Capparis spinosa* root extract administration for a period of 60 days did not cause body weight loss significantly, while the weight of testes, Cauda epididymis, seminal vesicle, and ventral prostate were significantly reduced. The lipid peroxidation and antioxidants levels i.e. superoxide dismutase, catalase, glutathione reduced, glutathione peroxidase, vitamin C, and Vitamin E in testes, Cauda epididymis, seminal vesicle, and ventral prostate were altered significantly ($P \leq 0.001$) after the 60 days treatment of *Capparis spinosa* extract when compared to the controls. The root extract feeding caused a marked reduction in the number of primary spermatocytes, secondary spermatocytes, and spermatids however spermatogonia population showed non-significant change. Sertoli cell population was also affected. The number of mature Leydig cells was decreased and degenerating cells increased proportionately. The seminiferous tubule and Leydig cell nuclear area were reduced significantly ($P \leq 0.001$) when compared to the controls. The protein and sialic acid content of the testes, Cauda epididymis, seminal vesicle, and ventral prostate were significantly ($P \leq 0.001$) decreased. The glycogen in testes and fructose in seminal vesicle was also significantly reduced, whereas the testicular cholesterol was elevated as compared with the controls. Reduced sperm count and motility resulted in a total suppression of fertility. The RBC and WBC count, hemoglobin, and hematocrit in whole blood whereas marker enzymes and glucose in serum were found to be within the normal range after the 60 days of *Capparis spinosa* extract treatment.

Conclusion: *Capparis spinosa* root extract may selectively act on developing germ cells mediated via Sertoli cells through increased oxidative stress or impairment of antioxidant defence system in reproductive organs of male rats, leading to suppression of fertility and suggests the feasibility of developing non-toxic, herbal male contraceptive drug.

Keywords: Antioxidants, *Capparis spinosa*, oxidative stress, spermatocytes

1. Introduction

Efforts are being made to develop antifertility products from plants. Ethnomedical literature contains thousands of references to plants pertaining to their use for reproductive health care [1]. *Capparis spinosa* (Capparaceae) is commonly known as 'Kabra' and is used in the traditional system of medicine in India. The root bark is used as an aperient tonic, expectorant, and analgesic, for the cure of rheumatism, paralysis, toothache, and tubercular glands. Young flower buds are antiscorbutic, stimulant, and aperient [2]. Experimentally, *Capparis spinosa* showed a number of pharmacological activities like anti-diabetic, anti-obesity, cholesterol-lowering, anti-hypertensive, anti-microbial, anti-inflammatory, antihepatotoxic, etc. [3]. However, no attention was paid to its possible effect on the reproductive system of mammals through oxidative stress. Although, several studies have suggested a definite link between oxidative stress and male infertility [4]. Therefore, the present experiment was designed to evaluate the suppression of fertility by methanol extract of *Capparis spinosa* root through oxidative stress in male albino rats.

2. Materials and methods

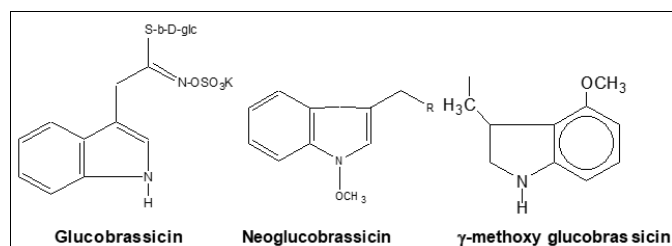
2.1 Test materials

Roots of *Capparis spinosa* were arranged and supplied by Amsar Private Ltd., Indore (India) vide batch no. 3328.

2.2 Extraction and isolation of compounds

Powder of root was extracted with methanol at 58 °C for 48 hrs. Methanol was removed by distillation and a brown semi-liquid mass was obtained. Brown mass was treated with acetonitrile for the removal of fatty parts soluble in acetonitrile. Acetonitrile was completely removed by distillation under reduced pressure leaving a brown semisolid mass. The fat-free extract so obtained was dried. A part of this extract was employed in the study on its biological activity and the rest, for the isolation of constituent compounds by means of chromatographic separation over Si-gel column 30 g of fat-free extract was chromatographed over 1 kg silica gel filled in a column of height 1.2 meters and 5 cm width. The column was eluted with various solvents in order of increasing polarity. From the column, the following compounds were isolated and structurally established by ¹H NMR, ¹³C NMR, MS, and IR spectral analysis [data not shown].

By eluting the column with pet ether: benzene (3:1), glucobrassicin and neoglucobrassicin were obtained. Further elution of the column with benzene: chloroform (1:3) yielded □-methoxy glucobrassicin [5].



2.3 Animals

Healthy, adult (4-5 months old) male albino rats of Wistar strain, weighing between 170-200 g obtained from Jamia Hamdard, Hamdard University, New Delhi, were used for the study. The rats were housed in plastic cages under standardized conditions (12 L:12 D, 25 °C ± 3 °C, and 35%-60% humidity). They were provided with the standard rat pellet diet (Hindustan Lever Limited) and water *ad libitum*.

2.4 Experimental design

Male rats of proven fertility were divided into two groups of 10 rats each. The daily dose of the plant extract was freshly dissolved in 0.5 ml of distilled water and administered to each treated animal every morning for 60 days.

Group I: Control rats received 0.5 ml/day of the vehicle.

Group II: Rats received extract at 100mg/kg/day for 60 days.

2.5 Fertility test

The mating tests were performed from day 55 to 60. The male rats cohabited with proestrus females at a ratio of 1:2. A vaginal smear was examined every morning for positive mating and the number of litters delivered was recorded.

2.6 Autopsy schedule

The male rats were kept in starved condition for 24 hours after the last dose delivery, then weighed and sacrificed under ether anesthesia, autopsied, the reproductive organs i.e. testes, epididymides, seminal vesicles, and ventral prostate were removed, cleared off fats and connective tissues, weighed and

kept at -20 °C. Blood was collected by cardiac puncture for hematology and serum biochemistry.

2.7 Sperm density and motility

The sperm density was assessed in cauda epididymis and testes. The tissues were mashed in physiological saline (0.9% NaCl) and the sperms were counted in a Neubauer's counting chamber. Epididymal spermatozoa were obtained through a puncture at the cauda with a disposable hypodermic needle, dispersed in saline solution and the motility was determined with a hemocytometer.

2.8 Antioxidant defence assay

Testes, cauda epididymis, seminal vesicle, and ventral prostate tissues were assayed for lipid peroxidation [6], superoxide dismutase [7], catalase [8], glutathione reduced [9], glutathione peroxidase [10], vitamin C [11] and vitamin E [12].

2.9 Biochemical studies

Total protein [13] and sialic acid [14] were performed in testes, cauda epididymis, seminal vesicle, and ventral prostate. Glycogen [15], cholesterol [16] contents in testes, and fructose [17] in seminal vesicles were determined.

2.10 Toxicology

2.10.1 Hematology

Blood samples were collected by cardiac puncture. Half of the whole blood was used for the analysis of blood corpuscles (RBCs), white blood corpuscles (WBCs), hemoglobin (Hb), hematocrit (packed cell volume, PCV), mean corpuscular hemoglobin (MCH), and mean corpuscular hemoglobin concentration (MCHC) [18-20].

2.10.2 Serum analysis

Rest of the blood was processed for serum separation. The serum-glucose, glutamate pyruvate transaminase (SGPT), glutamate oxalate transaminase (SGOT), lactate dehydrogenase (LDH), gamma-glutamyl transpeptidase (□-GTP), glutamate dehydrogenase (GDH), alkaline phosphatase (ALP) and glucose-6-phosphatase (G-6-PD) were estimated colorimetrically using reagent kits (Accurex Biomedical Pvt. Ltd., Mumbai).

2.11 Histopathological studies

Tissues were fixed in Bouin's fluid, passed through ascending series of ethanol than in xylene, and embedded in paraffin wax. Tissues were sectioned at 5 μm and stained with hematoxylin and eosin for the discrimination of the stages of spermatogenesis.

2.12 Quantitative analysis of cell population

The evaluation of cell population dynamics was based on the counts of each cell type per cross-tubular section. Various cell components were quantitatively analyzed using spherically appearing sections. Abercrombie's correcting factor was introduced [21] to correct for the better chance a big cell has to be counted. Mean tubular diameters were determined by tracing and measuring an average of 100 selected seminiferous tubules. The diameter of Leydig cell nuclei was measured at 800 X.

2.13 Statistical analysis

Data were expressed in mean ± SEM. The student's *t*-test was used to compare the significance of the difference and *P* ≤ 0.05 was set as significant.

3. Results

3.1 Body and organ weights

The impact of methanol extract of *Capparis spinosa* (*C. spinosa*) roots was found to have an antispermatogenic effect. The oral administration of *C. spinosa* extract at a 100mg/kg/day dose level for 60 days did not cause any significant change in the body weights of male rats whereas the weight of reproductive organs i.e. testes, epididymis, ventral prostate ($P \leq 0.001$), and seminal vesicle ($P \leq 0.01$) showed significant reduction (Table 1).

3.2 Sperm indices

As shown in Table 2, the treated rats showed a significant ($P \leq 0.001$) reduction in the sperm concentration of testes and cauda epididymides. The sperm motility of the cauda epididymides was also reduced significantly ($P \leq 0.001$), which resulted in the suppression of male fertility by 100%.

3.3 Antioxidant defence Assay

The activities of superoxide dismutase, catalase, glutathione reduced, glutathione peroxidase, vitamin C and Vitamin E in testes, cauda epididymis, seminal vesicle, and ventral prostate were decreased significantly ($P \leq 0.001$) in *Capparis spinosa* root extract-treated rats along with the significant ($P \leq 0.01$) elevation of lipid peroxidation, after the 60 days of treatment (Fig. 1-7).

3.4 Biochemical parameters

Table 3 depicts that the biochemical evaluations showed significant alterations after 60 days of treatment. The total protein contents of testes, cauda epididymis, ventral prostate ($P \leq 0.001$), and seminal vesicle ($P \leq 0.01$) were reduced significantly when compared to controls. The contents of sialic acid depleted significantly in testes, cauda epididymis, ventral prostate ($P \leq 0.001$), and seminal vesicle ($P \leq 0.01$). Testicular glycogen was reduced to a significant ($P \leq 0.001$) level whereas testicular cholesterol increased significantly ($P \leq 0.001$) in comparison to controls. The level of seminal fructose also showed a significant ($P \leq 0.01$) decline after the 60 days of treatment with *Capparis spinosa* root extract.

3.5 Cell population dynamics

Capparis spinosa root extract treatment brought about a significant reduction in most of the seminiferous tubular cell types. The population of primary spermatocytes (Preleptotene and pachytene) was decreased by 55.38% and 43.66%. The secondary spermatocytes also showed a decrease in their counts by 62.16%. The spermatogonial population did not show any significant alteration when compared to controls. The rounded spermatid cell population showed 53.57% diminished counts. Significant reduction ($P \leq 0.001$) in the diameter of the seminiferous tubule and Leydig cells nucleus was also observed. The number of mature Leydig cells decreased significantly ($P \leq 0.001$) whereas, degenerated Leydig cells increased at a significant ($P \leq 0.001$) level. However, fibroblast cells did not show any significant change. The number of Sertoli cells, as well as cross-sectional surface area, showed a notable depletion ($P < 0.001$) in comparison to controls (Table 4).

3.6 Toxicological analysis

The levels of blood RBCs, WBCs, Hb, PCV, MCV, MCH, and MCHC and serum-glucose, SGOT, SGPT, LDH, γ -GTP, GDH, ALP, and G-6 PD were shown within the pretreatment range after the 60 days of treatment compared with controls

[data not shown].

4. Discussion

The roots of *Capparis spinosa* have been proven to possess male antifertility activity by inducing the oxidative stress in the reproductive function of rats. The present study showed a significant reduction in the testicular weight following the oral administration of *Capparis spinosa* root extract indicates impairment at testicular, pituitary, or hypothalamic level. The reduction in testicular weight may be due to reduced tubule size, Spermatogenic arrest by oxidative stress, and inhibition of steroid biosynthesis in the Leydig cells [22]. *Capparis spinosa* root extract exerted a strong inhibitory effect on epididymides, seminal vesicle, and prostate gland as evidenced by the decrease in their weights. The reduction in the weight of accessory reproductive organs suggested the reduced availability of androgens [22].

An adequate number of sperms possessing normal function are necessary for successful fertilization, any deviation that alters sperm function leads to infertility. Although motility and density in cauda epididymis and testes were suppressed by *Capparis spinosa* root extract through highly reactive oxygen species (ROS) production, which serves as a second messenger system in many different cell types. This is because spermatozoa, unlike other cells, are unique in structure, and function and susceptible to damage by lipid peroxidation through increased oxidative stress. It is reported that excessive ROS production beyond critical levels overwhelms antioxidant defence strategies of spermatozoa in seminal plasma resulting in increased oxidative stress [23]. Elevated lipid peroxidation results in sperm immobilization, reduced acrosomal reaction, membrane fluidity, DNA damage, and also causes high frequencies of single and double DNA strand breaks in sperm [24, 25]. High levels of ROS disrupt the inner and outer mitochondrial membranes resulting in the release of cytochrome-c protein that activates caspase-induced apoptosis. Antioxidants act as free radical scavengers to protect spermatozoa against ROS below critical levels and compensate for the loss of sperm cytoplasmic enzymes as the cytoplasm is extruded during spermiogenesis, which, in turn, diminishes endogenous repair mechanisms and enzymatic defenses [26, 27].

The antioxidant system plays an effective role in protecting testes and other accessory reproductive organs below a critical threshold of reactive oxygen species thus preventing testicular dysfunction [28]. In view of the above fact, the results of the present study demonstrated the modulation of the antioxidant defence system of adult rat testes and accessory reproductive organs by *Capparis spinosa* root extract. Mammalian testes and other reproductive organs are rich in polyunsaturated fatty acids and are very much susceptible to attack by ROS resulting in the increased level of membrane lipid peroxides. The extent of cellular peroxidative processes depends on tissue antioxidant defence capacity. In general, alteration in the level of lipid peroxidation is considered as an indices of oxidative stress. Measurement of tissue TBARS is widely used to reflect the magnitude of lipid peroxidation and the several types of peroxidation products have made it a common choice to express lipid peroxidation [29].

The generation of ROS leading to oxidative damage due to O_2^- is contained by dismutation with SOD, which converts the reactive O_2 to H_2O_2 , if not scavenged by catalase cause lipid peroxidation by an increase in the generation of hydroxyl radicals. Hence, a decrease in SOD and catalase levels in testes and accessory reproductive organs in *Capparis spinosa*

root extract-treated rats may lead to an increased accumulation of reactive products resulting in tissue damage [25, 29]. GSH is a major thiol in living organisms, which plays a central role in coordinating the body's antioxidant defence processes. The tissue glutathione concentration reflects its potential for (i) detoxification (ii) preserving the proper cellular redox balance and (iii) its role as a cellular protectant. GSH has a likely role in sperm nucleus decondensation and spindle microtubule formation. Therefore, *Capparis spinosa* root induced depletion of GSH in testes and other accessory reproductive organs due to reactive oxygen intermediates, which can lead to instability of the mid-piece of spermatozoa, resulting in defective motility [29, 30].

Glutathione peroxidase plays a significant role in the peroxyl scavenging mechanism and in maintaining functional interaction of the cell membranes, spermatogenesis, sperm morphology, and sperm motility. It is suggested that the metabolic pathway of testosterone biosynthesis requires protection against peroxidation and will be affected by a decrease in the activity of this enzyme and ultimately cell death [28-30]. Nonenzymatic antioxidants vitamin C and E were also depleted in testes and other accessory reproductive organs following *Capparis spinosa* root extract treatment to rats due to free radical scavenging activity. Both the vitamins are major chain-breaking antioxidants in the seminal plasma and sperm membrane and protect sperm motility [30].

It is evidenced that testicular function would be altered by reduced protein content. Sialic acid acts as a "lubricant" to facilitate the downward movement of sperm and reduce

friction among spermatozoa [31]. Mukherjee *et al.* [32] studied the effect of flutamide on testes and accessory organs of male rats and also found a reduction in sialic acid contents. Cholesterol is involved in steroidogenesis in testes. Increased level of cholesterol in testes is attributed to decreased androgen concentration and increased fatty degeneration, which resulted in impaired spermatogenesis. Depletion in testicular glycogen was possibly attributed to the decreased number of post-meiotic germ cells. A reduction in fructose concentration in the seminal vesicle might be the result of a decreased secretory activity [31, 32].

Depletion in the number of spermatids, preleptotene, and pachytene spermatocytes may affect the androgen binding protein of Sertoli cells via its action in FSH with subsequent interference in sperm maturation and release due to oxidative stress [33]. Differentiation of primordial germ cells into spermatogonia and the consequent appearance of spermatogenic cycles are under the control of gonadotropins and testosterone, such control being possibly mediated by Sertoli cells which regulate cell cycle kinetics and influence both spermatogonia and preleptotene spermatocytes [32, 33]. Shrunken Sertoli cells in *Capparis spinosa* treated rat testes could be compared with cryptorchidism-like activity [34]. The total number of mature Leydig cells has a direct bearing on spermatogenesis. A reduction in number and dimensions are indicative of low androgen production affecting fertility due to cell damage or cell death. Decreased testicular protein could be co-related with the loss of germ cells as well as total membrane protein [33, 35].

Table 1: Showing the effects of *Capparis spinosa* root extract on the body weight and organs weight together with testicular histometry^a.

Treatment design	Bodyweight (g)	Organs weight (mg/100g b. wt.)				Semiferous tubular diameter (μm)	Leydig cell nuclear diameter (μm)
		Testes	Epididymis	Seminal vesicle	Ventral prostate		
Control	205	1350	575	585.25	445.75	268	11.10
[Group I]	± 25	± 22.50	± 10.50	± 20	± 11.60	± 9.0	± 0.02
<i>C. spinosa</i> root extract (100 mg/rat/day)	175	1115.25	400	487.95	252.35	187	5.07
[Group II]	$\pm 18^{\text{ns}}$	$\pm 15.80^{**}$	$\pm 21.10^{**}$	$\pm 18.20^*$	$\pm 7.09^{**}$	$\pm 2.15^{**}$	$\pm 0.56^{**}$

^avalues are mean \pm SEM (n = 10); ^{ns}non significant; * $p \leq 0.01$; ** $p \leq 0.001$ vs control (Student's *t*-test)

Table 2: Showing the effects of *Capparis spinosa* root extract on sperm dynamics and fertility of male rats^a.

Treatment design	Sperm Motility (%) Cauda epididymides	Sperm Density (million/ml)		Fertility (%)
		Testes	Cauda epididymides	
Control	72.40	4.62	42.50	100% (+)ve
[Group I]	± 0.81	± 0.11	± 0.92	
<i>C. spinosa</i> root extract (100 mg/rat/day)	28.71	1.65	6.52	100% (-)ve
[Group II]	$\pm 0.63^{**}$	$\pm 0.10^{**}$	$\pm 0.20^{**}$	

^avalues are mean \pm SEM (n = 10); * $p \leq 0.01$; ** $p \leq 0.001$ vs control (Student's *t*-test)

Table 3: Showing the effects of *Capparis spinosa* root extract on biochemical parameters of male rats^a.

Treatment design	Protein (mg/g)				Sialic acid (mg/g)				Glycogen Testes (mg/g)	Cholesterol Testes (mg/g)	Fructose Seminal Vesicle (mg/g)
	Testes	Cauda epididymis	Seminal vesicle	Ventral prostate	Testes	Cauda epididymis	Seminal vesicle	Ventral prostate			
Control	228.45	248	214	209.5	4.60	5.30	4.46	5.20	4.53	5.57	4.48
[Group I]	± 3.07	± 2.75	± 2.75	± 2.95	± 0.10	± 0.15	± 0.08	± 0.23	± 0.34	± 0.27	± 0.14
<i>C. spinosa</i> root extract (100 mg/rat/day)	188.67	185.00	194.5	189.45	3.78	3.15	4.06	3.30	2.43	8.30	3.90
[Group II]	$\pm 1.58^{**}$	$\pm 2.22^{**}$	$\pm 5.50^*$	$\pm 1.75^{**}$	$\pm 0.06^{**}$	$\pm 0.09^{**}$	$\pm 0.045^{**}$	$\pm 0.06^{**}$	$\pm 0.23^*$	$\pm 0.30^{**}$	$\pm 0.10^*$

^avalues are mean \pm SEM (n = 10); * $p \leq 0.01$; ** $p \leq 0.001$ vs control (Student's *t*-test).

Table 4: Showing the effects of *Capparis spinosa* root extract on testicular cell population in male rats^a.

Treatment design	Testicular cell counts (number/10 cross section)						Leydig cell differential counts			Sertoli cell nuclear area (μm^2)
	Spermatogonia	Sertoli cell	Preleptotene	Pachytene	Secondary spermatocytes	Rounded spermatids	Fibroblast	Mature	Degeneration	
Control	6.87	2.75	19.95	29.29	48.10	35.00	43.30	99.7	52.0	50.20
[Group I]	± 1.10	± 0.06	± 1.70	± 0.88	± 1.50	± 1.98	± 3.60	± 0.26	± 2.80	± 2.20
<i>C. spinosa</i> root extract (100 mg/rat/day)	5.30	2.05	8.90	16.50	18.20	16.25	56.80	51.90	98.30	28.50
[Group II]	$\pm 0.85^{\text{ns}}$	$\pm 0.12^{**}$	$\pm 1.45^{**}$	$\pm 1.80^{**}$	$\pm 2.35^{**}$	$\pm 2.80^{**}$	$\pm 2.80^{**}$	1.60 ^{**}	$\pm 1.50^{**}$	$\pm 1.75^{**}$

^a values are mean \pm SEM (n = 10); ^{ns}non significant; * $p \leq 0.01$; ** $p \leq 0.001$ vs control (student's *t*-test).

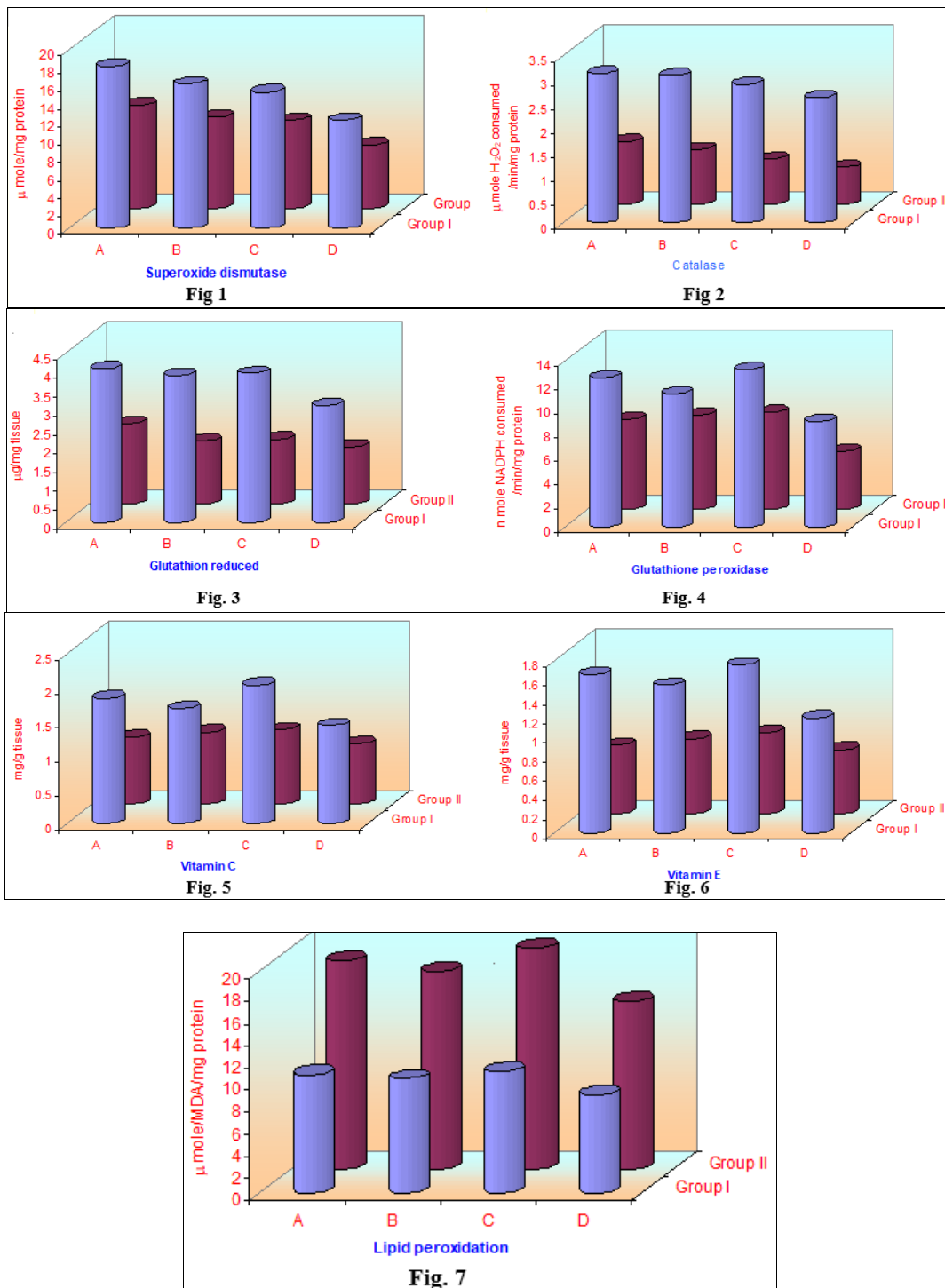


Fig 1 to 7: Showing alteration in antioxidant defence system of (A) Testes, (B) Cauda epididymis, (C) Seminal vesicle, and (D) Ventral prostate by *C. spinosa* root extract in group II, compared with control (group I) of male rats. Data are represented as mean \pm SEM from 10 observations.

4. In Conclusion

Available evidence indicates that the methanol extract of *Capparis spinosa* root is an orally effective, safe, non-toxic anti fertile agent that meets the essential criteria for male

contraception. However further studies on various dose levels are needed.

5. Conflict of interest

The authors declare no conflict of interest.

6. Acknowledgement

The authors are thankful to the respective authorities for providing the necessary facilities and support.

7. References

- Ain Q, David M, Shah Q, Ahmad M, Jahan S. Antifertility effect of methanolic leaf extract of *Chenopodium ambrosioides* Hook. in male Sprague Dawley rats. *Androl*. 2018;50:e13129.
- Kirtikar KR, Basu BD. Indian medicinal plants IInd. In: Singh B, Singh MP, editors. Vol II, Delhi. 1935, 195-197.
- Zhang H, Ma ZF. Phytochemical and pharmacological properties of *Capparis spinosa* as a medicinal plant. *Nutrients*. 2018;10:116-129.
- Ihsan AU, Khan FU, Khongorzul P, Ahmad KA, Naveed M, Yasmeen S, *et al*. Role of oxidative stress in pathology of chronic prostatitis/chronic pelvic pain syndrome and male infertility and antioxidants function in ameliorating oxidative stress. *Biomed Pharmacother*. 2018;106:714-723.
- Schraudolf H. Indole glucosinolates of *Capparis spinosa*. *Phytochem*. 1989;28:259-260.
- Okhawa H, Ohishi N, Yagi K. Assay for lipid peroxidation in animal tissue by thiobarbituric acid reaction. *Anal Biochem*. 1979;95:351-358.
- Marklund S, Marklund G. Involvement of superoxide anion radical in auto-oxidation of pyrogallol and a convenient assay for superoxide dismutase. *Eur J Biochem*. 1974;47:469-474.
- Aebi H. Catalase *in vitro*. In: Colowick SP, Kaplan NO, editors. *Methods in enzymology*. Vol 105. New York: Academic Press. 1984, 121-126.
- Moron MA, Dipierre JW, Mannervick B. Levels of glutathione, glutathione reductase and glutathione-S-transferase activity in rat lung and liver. *Biochem Biophys Acta*. 1979;582:67-78.
- Paglia DE, Velentine WM. Studies on the quantitative and qualitative characterization of erythrocyte glutathione peroxidase. *J Lab Clin Med*. 1967;70:158-169.
- Omeye ST, Turnbull JD, Sauberlich HE. Selected methods for the determination of ascorbic acid in animal cells, tissues and fluids. *Meth Enzymol*. 1971;62:1-6.
- Baker H, Frank O, Angelis B, Feingold S. Plasma tocopherol in man at various time after ingesting free or acetylated tocopherol. *Nutr Rep Int*. 1980;21:531-536.
- Lowry OH, Rosebrough MJ, Farr AL, Randall RJ. Protein measurement with folin phenol reagent. *J Biol Chem*. 1951;193:265-275.
- Warren L. A thiobarbituric acid assay to sialic acid. *J Biol Chem*. 1959;264:1971-1975.
- Montgomery R. Determination of glycogen. *Arch Biochem Biophys*. 1957;67:378-381.
- Zlatkis A, Zak B, Boyle AJ. A new method for the direct determination of cholesterol. *J Lab Clin Med*. 1953;41:486-492.
- Mann T. Fructose, polyols and organic acid. In: *Biochemistry of Semen and of the male reproductive tract*. London: Methuen and Co; 1964, 237-249.
- Natelson S. Routine use of ultramicro methods in the clinical laboratory. *Am J Clin Pathol*. 1951;21:1153-1172.
- Crosby WH, Munn JI, Furth FW. Standardizing a method for clinical haemoglobinometry. *US Armed Forces Med J*. 1954;5:693-703.
- Lynch MJ, Raphael SS, Mellor LD, Spare PD, Inwood MJH. *Medical laboratory technology and clinical pathology*. Philadelphia: WB Saunders Company. 1969.
- Abercrombie M. Estimation of nuclear population from microtome sections. *Anat Res*. 1946;94:238-243.
- Jain S, Jain A, Paliwal P, Solanki SS. Antifertility effect of chronically administered *Tabernaemontana divaricata* leaf extract on male rats. *Asian Pac J Trop Med*. 2012;5:547-551.
- Gil-Guzman E, Ollero M, Lopez MC, Sharma RK, Alvarez JG, Thomas AJ Jr. Differential production of reactive oxygen species by subjects of human spermatozoa at different stages of maturation. *Hum Reprod*. 2001;16:1922-1926.
- Armstrong JS, Rajasekaran M, Chamulitrat W, Gatti P, Hellstrom WJ, Sikka SC. Characterization of reactive oxygen species induced effects on human spermatozoa movement and energy metabolism. *Free Radic Biol Med*. 1999;26:869-875.
- Aitken RJ, Krausz C. Oxidative stress, DNA damage and the Y-chromosome. *Reprod*. 2001;122:497-505.
- Aitken RJ, Clarkson JS, Fishel S. Generation of reactive oxygen species, lipid peroxidation, and human sperm function. *Biol Reprod*. 1989;41:183-197.
- Mari M, Wu D, Nieto N, Cederbaum AI. CYP 2E1-dependent toxicity and up-regulation of antioxidant Genes. *J Biomed Sci*. 2001;8:52-60.
- Lewis SE, Sterling ES, Young IS, Thompson W. Comparison of individual antioxidants of sperm and seminal plasma in fertile and infertile men. *Fertil Steril*. 1997;67:142-147.
- Wagner H, Julie W, Cheng JW, Ko EY. Role of reactive oxygen species in male infertility: An updated review of literature. *Arab J Urol*. 2018;16:35-43.
- Jedrzejowska RW, Wolski JK, Hilczer JS. The role of oxidative stress and antioxidants in male fertility. *Cent European J Urol*. 2013;66:60-67.
- Verma PK, Sharma A, Mathur A, Sharma P, Gupta RS, Joshi SC, *et al*. Effect of *Sarcostemma acidum* stem extract on spermatogenesis in male albino rats. *Asian J Androl*. 2002;4:43-47.
- Mukherjee M, Chattopadhyay S, Mathur PP. Effect of flutamide on the physiological status of epididymis and epididymal sperms. *Andrologia*. 1992;24:113-116.
- Gupta RS, Yadav RK, Dixit VP, Dobhal MP. Antifertility studies of *Colebrookia oppositifolia* leaf extract in male rats with special reference to testicular cell population dynamics. *Fitoterapia*. 2001;72:236-245.
- Jegou P, Lows AO, Dekretser DM. The effect of cryptorchidism and subsequent orchidopexy on testicular function in adult rats. *J Reprod Fertil*. 1983;69:137-145.
- Monet-Kuntz M, Hochereau-de Reviers T, Terqui M. Variations in testicular androgen receptors and histology of the lamb testis from birth to puberty. *J Reprod Fertil*. 1984;70:203-210.